

No. 404703

Pan No. AAKCC6003A



**Care For**  
Appetite Foundation

**ANIMAL AID**  
Support Animal Aid

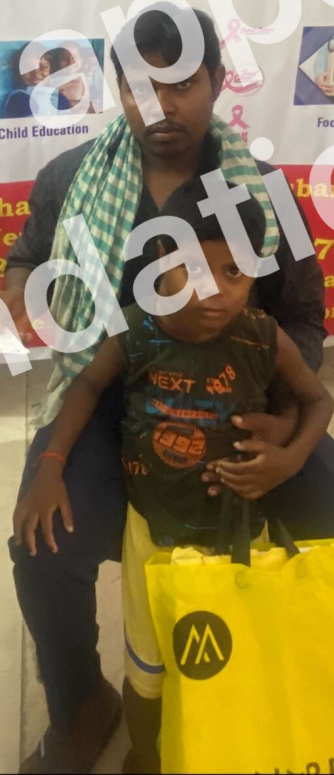**Child Education**

**FOOD DISTRIBUTION**  
Food Distribution

897, F/F, Cha  
Ne  
Mob.: 798

barakpur  
7740  
ail.com  
n.com

Care for appetite foundation







Care for appetite  
foundation

CONFIDENT STYLE  
NEXT  
MAKES STRONG  
1992




सेवा में

श्रीमान Care for appetite foundation  
owner महोदय

महोदय निवेदन इस प्रकार है कि मेरा नाम दया नन्द मान्जा है। मैं बिहार का रहने वाला हूँ। मेरे बच्चे का नाम अनुज कुमार है जिसका आयु सात वर्ष है मेरा बच्चा अनुज कुमार जो कि गले में कैंसर का बिलार से पीड़ित है मेरा बच्चा पिछले 18 महीने से इस बिलार से सफर कर रहा है। मेरे बच्चे का हला बहुत ज्यादा खरब है इसका इलाज दिल्ली में एम्स हस्पताल में चल रहा है। डॉक्टर ने मेरे बच्चे के इलाज के लिए जो दवाइयाँ, इंजेक्शन, ऑपरेशन बताया है जिसका खर्चा बहुत ज्यादा है। मैं एक वरिष्ठ परिवार से हूँ। और मैं मजदुरी करता हूँ।

महोदय से हाथ जोड़कर निवेदन है कि मेरे बच्चे का इलाज करने में सहभाग करे। अपना आँत कृपया होगा। मैं अपना जिम्मा बर आबरा रहूँगा।



प्रार्थी

दया नन्द मान्जा

दया नन्द मान्जा



भारत सरकार

Government of India

अनोज कुमार

Anoj Kumar

पिता : दयानंद मांझी

Father : Dayanand Manjhi



जन्म तिथि / DOB: 03/07/2016

पुरुष / Male

यह आधार 5 वर्ष की उम्र तक ही वैध है

9421 9895 2113



बाल आधार

मेरा **आधार**, मेरी पहचान





भारत सरकार

Government of India



दयानंद मांझी

Dayanand Manjhi

जन्म तिथि/ DOB: 12/06/1993

पुरुष / MALE



8421 7908 3191

मेरा आधार, मेरी पहचान



भारतीय विशिष्ट पहचान प्राधिकरण

Unique Identification Authority of India

पता: आत्मज: दयानंद मांडी, ग्राम  
कढौना पोस्ट सिंघौरा, वजीरगंज, गया,  
वजिरगंज, बिहार, 805131

Address: S/O: Dayanand Manjhi,  
gram kadhauna post singhaura,  
Wazirganj, Gaya, Wazirganj,  
Bihar, 805131

9421 9895 2113



1947



help@uidai.gov.in

WWW

www.uidai.gov.in

# NAVJEEVAN HOSPITAL

: 9214329222  
☎ 01493-222088  
Fax : 01493-222325

E-mail : hospitalnavjeevan@yahoo.com

NEAR GANPATI PLAZA, PHOOL BAGH CHOWK, BHIWADI-301 019

**Dr. Ajay Goyal**

M.B.B.S., M.S.

General & Laproscopic Surgeon

**Dr. Garima Goyal**

M.B.B.S., D.G.O.

Obstetrician & Gynaecologist

Date 4/5/23

Name :- Aanya

Age / Sex :- 7 / m

OPD No. :- 8528

*Large Swelling Rt Side Neck - Ingu*

*FNAL ? Hodgkin's disease  
(NHL)*

Care for appetite  
foundation

*Refer to Higher Center -  
Paed. Surgeon  
Kalindi Hospital / R*

*Delhi*

*[Signature]*

पी.डी. समय : प्रातः 10 बजे से 2 बजे तक तथा सायं 6 बजे से 8 बजे तक  
रविवार सायं अवकाश रहेगा।



23-26301 14/06/23



# अ० भा० आ० सं० अस्पताल / A.I.I.M.S. HOSPITAL

## बहिरंग रोगी विभाग / Out Patient Department

अस्पताल के अन्दर धूम्रपान मना है। / SMOKING IS PROHIBITED IN HOSPITAL PREMISES



शरीरमाद्यं खलु धर्मसाधनम्

कक्षा / Room

उपचारिका  
UHD: 108703102  
Dept No: 20230220002890

डा. संदीप अग्रवाल  
Dr. Sandeep Agrawal  
Paed Surgery O.P.D.  
(शुक्रवार) Friday

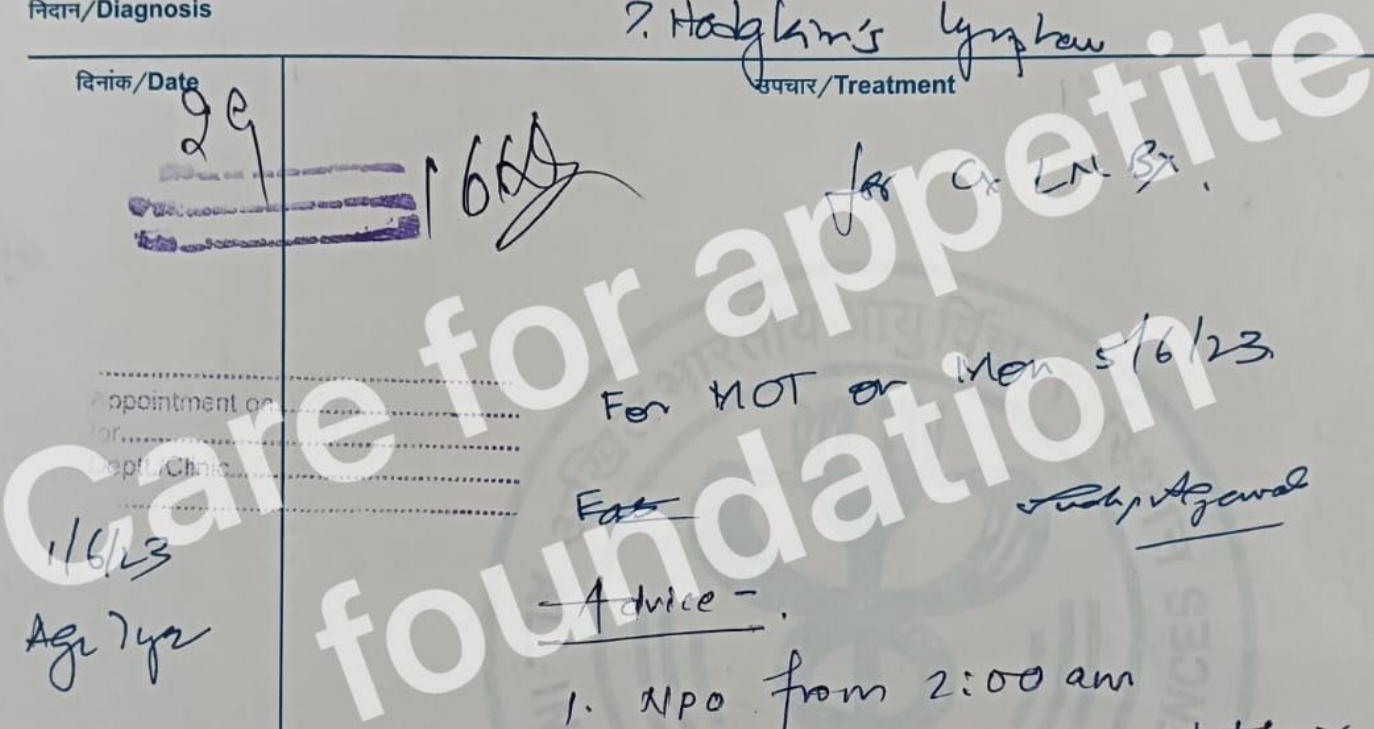
ब० र० वि० पंजीकृत सं० / O.P.D. Regn. No.

<p>अणुज कुमार ANUJ KUMAR TY M 27D / M (पुरुष) S: ODAYANAND MANJHI Add: KADHUNA THANA WAZIRGANJ SINGHAURA GA YA, BIHAR, Pin: 805131, INDIA Mob: 8002752985 Follow Up ... General ₹ 0 Reporting: 8:00 AM-9:00 AM</p>	<p>G-31 Unit-I Paediatric Surgery OPD Queue No: F36 02/06/2023 मंगल, शुक्र FRI</p>		<p>आयु Age</p>	<p>पता / Address</p>
--	--	--	--------------------	----------------------

### निदान / Diagnosis

? Hodgkin's lymphoma

दिनांक / Date	उपचार / Treatment
<p>29 <del>29</del> <del>29</del></p>	<p>for Cr LM Bx</p>
<p>Appointment on for Dept / Clinic 1/6/23 Age 7yr</p>	<p>For NOT on Mon 5/6/23 Fast Advice - 1. NPO from 2:00 am 2. Report to MCH 2nd floor OT complex at 7:30 am CBC report / Rf - Shree</p>



CLEAN AND GREEN AIIMS / एम्स का यही संकल्प, स्वच्छता से काया कल्प  
 अंगदान-जीवन का बहुमूल्य उपहार / ORGAN DONATION - A GIFT OF LIFE  
 O.R.B.O., AIIMS, 26588360, 26593444, www.orbo.org Helpline - 1060 (24 hrs service)







अस्पताल / A.I.I.M.S. HOSPITAL  
 बहिरंग रोगी विभाग / Out Patient Department  
 अस्पताल के अन्दर धूम्रपान मना है। SMOKING IS PROHIBITED IN HOSPITAL PREMISES



शरीर

भारत स्वास्थ्य विज्ञान  
 UHID: 106703102  
 Dept No: 20230220002890

कमरा / Room

G-31  
 Unit-I  
 Paediatric Surgery OPD  
 Queue No: F21

डा. संदीप अग्रवाल  
 Dr. Sandeep Agarwala  
 Paed Surgery O.P.D.  
 (सकलवार) Friday

एकक  
विभाग

रोविं पंजीकृत सं/O.P.D. Regn No.

अनुज कुमार  
 ANUJ KUMAR  
 7Y 1M 14D / M(पुरुष)  
 S/O DAYANAND MANJHI  
 Add: KADHUNA THANA WAZIRGANJ  
 SINGHAURA GAYA, BIHAR, Pin 805131,  
 INDIA  
 Mob: 8002752985 Follow Up...  
 General P O Reporting: 10.00  
 AM-11.00 AM

20/08/2023  
 भंगल, गुल

आयु  
Age

पता / Address

निदान / Diagnosis

Cervical L4/5

दिनांक / Date

उपचार / Treatment

5

Hodgkins lymphoma

Appointment on  
 for  
 Deptt./Clinic

Dr Sameer Bakshi

HPB (14/6/23)

c/p/w A Vesket for

Classed the mod cellular

for Dr Sameer Bakshi for further management

Suture removal

R. No 38





0230229002890

नकदी रसीद / CASH RECEIPT  
 अखिल भारतीय आयुर्विज्ञान संस्थान / ALL INDIA INSTITUTE OF MEDICAL SCIENCES  
 अंसारी नगर, नई दिल्ली-110029 / Ansari Nagar, New Delhi-110029

दूरभाष { 26588500  
 Phones { 26588700

रसीद संख्या / Receipt No-28/1645/202324

जमाकर्ता / Received From Hospital Receipts

ओ.पी.डी./यू.एच.आई.डी. (OPD/AMBIDN) Mons 30 Days

के नामे / ON ACCOUNT OF (OPD)

दिनांक / Dated : 05/06/2023

रोगी प्रकार / Patient Type :

कमरा संख्या / Room No. :



SI No.	Service Name	Amount
1	ADVANCE SHORT ADMISSION	60.00

Printed on 05 Jun 2023 07:28:49 AM

भुगतान का प्रकार / Payment Mode :

रुपये / INR (Rs.) :

Care for appetite  
 foundation



अणुज कुमार  
 ANUJ KUMAR  
 TY M 21D / (म/पुरुष)  
 SIDDIYANAND MANJHI  
 Add: KADHUNA THANA WAZIRGANJ  
 SINGHURIA GAYA, BHAR, Pin 805131  
 INDIA  
 Mob: 8002752985 New Patient General F 0 Reporting: 10.00 AM-11.00 AM

डॉ. संदीप अग्रवाल  
 Dr. Sandeep Agarwal  
 Paed Surgery O.P.D.  
 (शुक्रवार) Friday  
 रोगी सं. / O.P.D. Regn. No. \_\_\_\_\_  
 आयु / Age \_\_\_\_\_  
 पता / Address \_\_\_\_\_

निदान / Diagnosis ? Hodgkins Lymphoma & Evaluation

दिनांक / Date ~~30/05/23~~  
 उपचार / Treatment Pt. was called on 26/5/2023 in PSOP for scheduling for Lymph node bx & GA.

बात मापचिकित्सा  
 UHID: 106703102  
 Dept No: 20230220002890  
 G-31 Unit-I  
 Paediatric Surgery OPD  
 Queue No: F27  
 30/05/2023  
 Add: KADHUNA THANA WAZIRGANJ  
 SINGHURIA GAYA, BHAR, Pin 805131  
 INDIA  
 Mob: 8002752985 Follow Up... General F 0 Reporting: 10.00 AM-11.00 AM

Pt. didn't attend the OPD  
 Adv: \_\_\_\_\_

दिनांक / Date ~~30/05/23~~  
 उपचार / Treatment To see on 2/6/2023 at 8:30 am for scheduling for L node bx & GA.

दिनांक / Date 2/6/2023  
 उपचार / Treatment for Prof. S. Agarwal  
 Dept./Clinic P/S



D.L. No. : DL-2022000142

TAX/RETAIL INVOICE/CASH MEMO

GSTIN : 07ALGPJ9871M1ZD

KNOW AIDS

# + ONKAR MEDICOS +

NO AIDS

Deals In : Medicines, Surgicals, Anti-cancer Drugs,  
Nephrology & Health Care Products  
E-mail : onkarmedicos1@gmail.com

Ph. : 011-26176555  
Mobile : 7838883555

Shop No.-1, AIIMS Subway, New Delhi - 110023

DEALS IN : MEDICINES, SURGICALS & COSMETIC PRODUCTS

Bill No. : 25076

Date :

20/06/2023

Pt. Name : ANUJ KUMAR

Pr. by Dr. :

Address

QTY.	DESCRIPTION	BATCH NO.	EXP. DT.	HSN	GST	AMOUNT
------	-------------	-----------	----------	-----	-----	--------

1 PARATAS 250MG SYP

L-22362

12/24 3004 12.00

44.35

Care for appetite  
OPEN ALL DAYS

ALL DEBIT / CREDIT CARDS ARE ACCEPTED HERE  
Indian & Imported Medicine H.L.V. & Chemicals  
FSSAI NO 36979040872990990

NOTE : CUTTING STRIPS & FRIDGE TEMS (WITHOUT ICE) WILL NOT BE RETURNED  
MEDICINE WILL BE RETURNED WITHIN 10 DAYS WITH BILL FROM SALE DATE

GROSS AMOUNT :	44.35
LESS DIS.% :	0.00
NET AMT. (R/O) :	44.00

Rupees

A Trusted Name for Genuine Medicines

• Prices of Medicines are inclusive of GST.  
• All Disputes Are Subject To Delhi Jurisdiction

• Goods once sold will not be taken back.  
(Computer Generated Invoice)

For Onkar Medicos

OPEN ALL DAYS OPEN ALL DAYS OPEN ALL DAYS

OPEN ALL DAYS OPEN ALL DAYS OPEN ALL DAYS

E & O E



अखिल भारतीय आयुर्विज्ञान संस्थान  
ALL INDIA INSTITUTE OF MEDICAL SCIENCES

अंसारी नगर, नई दिल्ली-110029

ANSARI NAGAR, NEW DELHI-110029

नाभिकीय चिकित्सा विभाग

DEPARTMENT OF NUCLEAR MEDICINE

CLINICAL PET FACILITY

(CHALLAN FORM)

AIIMS UHID No. 106703102

Date 11/5/23

Asstt. Cashier Central Admission Office may please receive a sum of  
Rs. 5000 / 7500 / 4000 / - (Rupees) Five Thousand / Seven Thousand Five hundred / Four Thousand

Vide D.D. No. \_\_\_\_\_ from Shri/Dr./Mrs./Ms. Arjun Kumar  
UHID No. \_\_\_\_\_ Clinical Dept. / Unit NMD Ward/Bed No. \_\_\_\_\_ OPD/CR/  
No. \_\_\_\_\_ on account of charges for PET/Scan, Creditable to Sub-head "PET Charges".

[Signature]  
Officer Incharge Dept.

R. No. \_\_\_\_\_ Dt. \_\_\_\_\_ for \_\_\_\_\_  
Rs. \_\_\_\_\_ (Rupees \_\_\_\_\_)

Cashier



## DEPARTMENT OF PATHOLOGY

Shaheed Hasan Khan Mewati Govt. Medical College Nalhar (Mewat) Haryana

**HISTOPATHOLOGY/CYTOLOGY REPORT LAB**

Name Arif kumar Age 6 y Sex Male  
 Ward ENT Bed No. \_\_\_\_\_ C.R./OPD No. 642570  
 Nature of tissue sent FNAC Swelling Right side Neck Income \_\_\_\_\_  
 HISTOPATHOLOGY/CYTOLOGY No. PM-391723 Dated 25-4-23

CLINICAL DIAGNOSIS.....

## REPORT

FNAC Swelling Right side Neck

Microscopy - Smears prepared show some singly scattered large cells having single nuclei and some binucleate forms. These cells have round to oval nuclei with prominent large nucleoli and moderate amount of cytoplasm. Few clusters of epithelioid cells also seen. Background shows mixed population of lymphoid cells, eosinophils, plasma cells and RBCs.

Impression - Cytologically possibility of Hopkin's disease to be considered.

Advice - Biopsy followed by DHC for definite diagnosis

Date Received .....

Date Reported 26-4-23

Pathologist

Dr. Shilpa Gang

## Directions for sending tissue for Histopathological Examination

- Tissue after removal should be transferred in 10% formalin immediately.
  - Ratio of tissue to formalin should be 1 to 15 for proper fixation.
  - Prepare formalin (10%) as follows :—
 

Formalin	10 ml.
Tap Water	90 ml.
- If clinical summary is not given, the report is likely to be with held or delayed.
- Please state clearly, if any specific information is desired from laboratory.



24/5/2023

Ht = 107.5cm  
Wt = 16.9kg

- Biopsy - not done

NIV - 25/5/2023 - to discuss & prog.  
Sanderu Sir for biopsy

From 12) b

*Sal*

25/3/23

For LM Bx

To see in OPD for  
data for LM Bx ↓ GA

G-3)

21/06/23

*Shy Aguda*

- Bx s/o - cHL - mic subtype
- 10 donation pending
- R/V 23/06/23 @ CBCUW Rm.

*Shy*

23/6/23

more

10. Blood donation

PLU 28/6/23

*Shy*



डा. बी. आर. अम्बेडकर संस्थान रोटरी कैंसर अस्पताल  
Dr. B.R. Ambedkar Institute Rotary Cancer Hospital

अ.भा.आ.  
बहिरंग

Paid Online

अस्पताल के अन्दर

OPR-6

Dr. S. Bakshi

एकक/Unit

विभाग/Department

नाम/Name

DR. B.R.A. IRCH, AIIMS, NEW DELHI

IRCH No. 295646

Reg. Date-10/05/2023

Clinic Paed. Lymphoma Leukemia Clinic

Clinic No. 2023/20929

Deptt. MEDICAL ONCOLOGY

General



/Date of Birth

नाम अणुज कुमार

UHID-106703102

Name ANUJ KUMAR

S/O- DAYANAND MANJHI

Sex/Age M/7Y

Phone No. 8002752985

Room 13 (Shift Morning)

INDIA WAZIRGANI SINGHAJRA GAYA, BIHAR.

निदान/Diagnosis

? Hodgkin Lymphoma ↓ evaluation

दिनांक/Date

उपचार/Treatment

10 MAY 2023

Adv

→ CBC / LFT / URT / Vial markers / coagulation

→ USG guided biopsy from left Cervical Lymph node

→ Echo - 2D

→ Whole body PET - CT

→ Blood donation - 30

- N/A - 22/5/2023

reports

- CXR - PA view

AIIMS MAIN  
NEW EMERGENCY  
BLOOD BANK

for wedge Bx ↓ GA

su in old fridy 12/5/23

631

*[Signature]*

hash  
6ms

अंगदान-जीवन का बहुमूल्य उपहार/ORGAN DONATION - A GIFT OF LIFE

O.R.B.O., AIIMS, 26588360, 26593444, www.orbo.org Helpline - 1060 (24 hrs service)

बाहर से आने वाले रोगियों के लिए धर्मशाला की सुविधा उपलब्ध है/Dharamshala facility is available for outstation patients

0810258668 - इशारा

011-26588360 - 011-26593444



**<sup>18</sup>F-FDG WHOLE BODY PET-CT STUDY**

Patient Name: ANUJ KUMAR		Age/Sex: 7 Y/M
Study ID: FDGN/30732/23	UHID: 106703102	Date: 16.05.2023

**Indication:** ? Hodgkins lymphoma (HL); C/o right sided neck swelling x 9 months.  
**FNAC(Pvt):** S/o HL. PET-CT for baseline evaluation.

**Procedure:** PET-CT acquisition was done 60 minutes after injection of 10 mCi <sup>18</sup>F-FDG by intravenous route, from the level of orbits to mid-thigh. CT was done for attenuation correction and anatomical localization.

**PET-CT Findings:**

**Head and Neck:** FDG avid enlarged and discrete and conglomerated (mass like) right cervical level I-V and right supraclavicular/infraclavicular lymph nodes noted (largest right level ~II measuring 4.1x2.1 cm). Increased FDG uptake noted in bilateral palatine tonsils with few sub-centimetric bilateral cervical lymph nodes – infective. Visualized paranasal sinuses, skull base, pharynx, larynx and thyroid do not show any abnormality on CT.


**Thorax:** FDG avid right paratracheal (3.8x2.4cm), subcarinal lymph nodes noted. Mildly FDG avid sub-centimetric bilateral axillary (1.1x0.7cm) lymph nodes noted with most showing loss fatty hilum. Physiological FDG uptake is seen in the myocardium. No abnormal FDG uptake noted in the lungs, and thoracic wall. Lungs, large airways, pleura, heart and great vessels appear normal on CT.


**Abdomen-Pelvis:** FDG avid aortocaval, paraaortic (largest ~1.5x1.1cm) and right retrocrural lymph nodes noted. Spleen measures ~8 cm in CC span and shows heterogeneous increased FDG uptake with areas of focal FDG uptake with no CT findings. Liver measures 14 cm in CC span. Few sub-centimetric bilateral inguinal lymph nodes noted with preserved fatty hilum. Normal FDG distribution is noted in the kidneys, gastrointestinal tract and urinary bladder. Biliary ducts, gall bladder, kidneys, stomach, adrenals, pancreas, retroperitoneum, bowel and urinary bladder appear normal on CT. No ascites is noted.

**Musculo-Skeletal System:** Physiological FDG distribution is seen in the visualized axial and appendicular skeleton.

**IMPRESSION:**

**Metabolically active lymph nodes on both sides of the diaphragm with splenic involvement.**

  
Dr T Kishan Subudhi  
Senior Resident

  
Prof. Rakesh Kumar  
Consultant





# LABORATORY ONCOLOGY UNIT, Dr B.R.A. IRCH, AIIMS, New Delhi & NCI-JHAJJAR, AIIMS

## Requisition Form for Routine Investigations

*Gate no 4*

UHID : \_\_\_\_\_

Name : \_\_\_\_\_

Age/Sex : *21* \_\_\_\_\_

- Clinical Diagnosis:
- Clinical Details:
  
- Payment status:
  - Paying
  - EHS (No :)
  - Exempted by (Sign and Stamp)

### Investigation Requested

Parameters	Cost	Parameters	Cost	Parameters	Cost	Parameters	Cost
CBC+DLC	Free	Total Bilirubin	Free	FSH	Free	HIV	Free
CBC+DLC+ Reticulocyte	Free	Direct Bilirubin	Free	LH	Free	HBsAg	Free
PT	Free	SGPT/ALT	Free	Estradiol	Free	HCV	Free
INR	Free	SGOT/AST	Free	Progesterone	Free	IgG	Free
APTT	Free	Total protein	Free	Cortisol	Free	IgA	Free
TT	Free	Albumin	Free	Vitamin D	Free	IgM	Free
D Dimer	Free	Alkaline Phosphotase	Free	Testosterone	Free	AFP	Free
Fibrinogen	Free	GGT	Free	TSH	Free	CA125	500
Glucose R	Free	Amylase	Free	FT3	Free	CA19.9	Free
Glucose F	Free	Lipase	Free	FT4	Free	CEA	Free
Glucose PP	Free	Magnesium	Free	T3	Free	PSA	Free
GTT-50g Glucose	Free	Cholesterol	Free	T4	Free	Free PSA	Free
GTT-75g Glucose	Free	Triglyceride		Vitamin B12	Free	β-HCG	Free
GTT-100g Glucose	Free	VLDL		Folate	Free	HbA1c	Free
Urea	Free	LDL		Homocysteine	Free	<b>Requesting Doctor</b> Name _____  Sign <i>[Signature]</i>  Seal _____	
Creatinine	Free	HDL	Iron	Free			
Uric Acid	Free	LDH	Transferrin	Free			
Calcium	Free	CRP	Ferritin	Free			
Phosphorus	Free	IL-6	Free	TIBC	Free		
Sodium	Free	Procalcitonin	1350	Troponin	Free		
Potassium	Free	Prolactin	Free	CK-NAC	Free		
Chloride	Free	PTH	Free	CK MB	Free		

Remarks: .....





**Department Of Pathology**  
**All India Institute Of Medical Sciences**  
**Delhi**

Tel: +91-11-26588500/26588700; Fax: +91-11-26588500/26588700

Patient Name:	Anuj	Acc. No:	2326301
F/H Name:	Dayanand	Hosp. Reg. No.:	106703102
Age/Sex:	7 Y/Male	UHID No.:	---
Clinic/Dept/Unit:	N/A/Unit 1	Consultant Incharge:	Dr. N/A
Reg Date:	06-06-2023	Reporting Date:	14-06-2023

**Histopathology Report**

**Report Findings:**

Biopsy from right level II cervical lymph node is in multiple pieces together measuring 1.8x1x0.5cm.

-Sections show diffuse effacement of lymph node architecture by polymorphous population of lymphocytes histiocytes, eosinophils, neutrophils and large atypical cells with prominent eosinophilic nucleoli with perinucleolar halo.

These atypical cells are immunopositive for CD15, CD30, PAX-5 (Dim) and EBV-LMP1, while are negative for CD20 and CD3.

Impression: Classical Hodgkin lymphoma, mixed cellularity subtype.

Reporting Incharge: Dr. Balamurugan T

Reporting SR: Dr. Priyanka Mani

Verify By: Dr. Priyanka Mani

22/04/23 9810258068



**MODERN**  
ISO 9001 : 2008 CERTIFIED

**ULTRASOUND**  
& Diagnostic Centre

Patient's Name	Mast. Anoj Kumar	Age & sex	06 Y/M
Referred by	S.H.K. Nuh	Date	20-Apr-23

### USG - NECK

Both thyroid lobes are normal in size, shape and echotexture.

No focal or diffuse lesion is noted.

The isthmus measures normal in size.

The visualised submandibular and parotid glands show normal echotexture bilaterally.

The carotid arteries and the IJV appear normal in course and caliber as seen on gray scale.

**Multiple small sized cervical lymph nodes seen on right side of neck, largest 35 x23 mm. Most of these nodes are coalesced together and extending along level III, level II, upper jugular, submandibular, inferior auricular, transverse cervical and posterior triangle region. Most of these nodes are hypoechoic.**

No other abnormal soft tissue is seen in the neck.

#### OPINION:

Right Sided Cervical  
Lymphadenopathy (? Tubercular).

ADV ~ FNAC & MTX Correlation.

Please correlate clinically.

10/5/23  
 Distal R# 13  
 Ped LL - R# 13  
 Sameer Bakhshi  
 Deepam

**Dr. Ravinder Kumar**  
Consultant Radiologist  
RMC No.- 16236

डॉ. समीर बखशी/Dr. SAMEER BAKHSHI  
आचार्य चिकित्सा अनुसंधान विभाग/Prof. Medical Oncology  
आई.सी.ए.ए. रो.के.अ./Dr. B.R.A., I.R.C.H.  
दिल्ली/AIIMS, New Delhi-29  
RMC Registration No. 1893.  
मोबा. : 09414891464 E-mail : modernultrasound@gmail.com

CP-135, Near Govt. Hospital, Samtel Road, Bhiwadi, Distt. Alwar (Rajasthan) Tel. : 01493-617439; Mob. : 09414891464 E-mail : modernultrasound@gmail.com  
Facilities:- MRI • Multi Slice CT Scan • 4D-Ultrasound • Echo-Cardiography • Colour Doppler • Mammography • Digital X-Ray • OPG • TMT • ECG • EEG • PFT • Laboratory

This is a professional opinion and not the final diagnosis. The report is to be correlated clinically and with lab reports. This report is not valid for medical insurance.